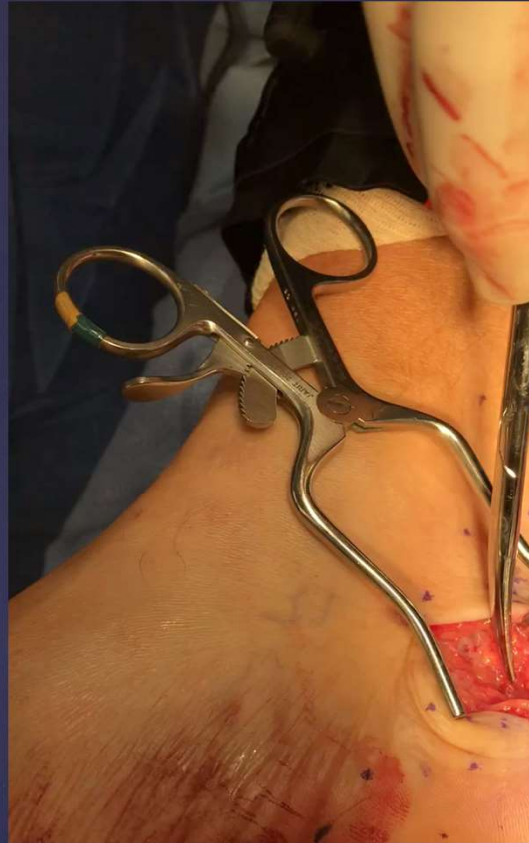
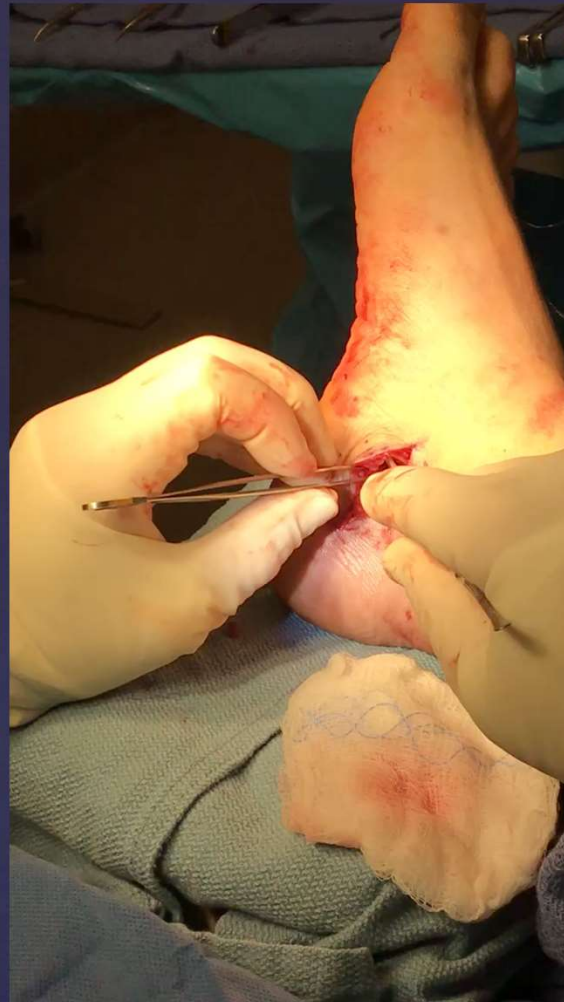
MIS nerve releases

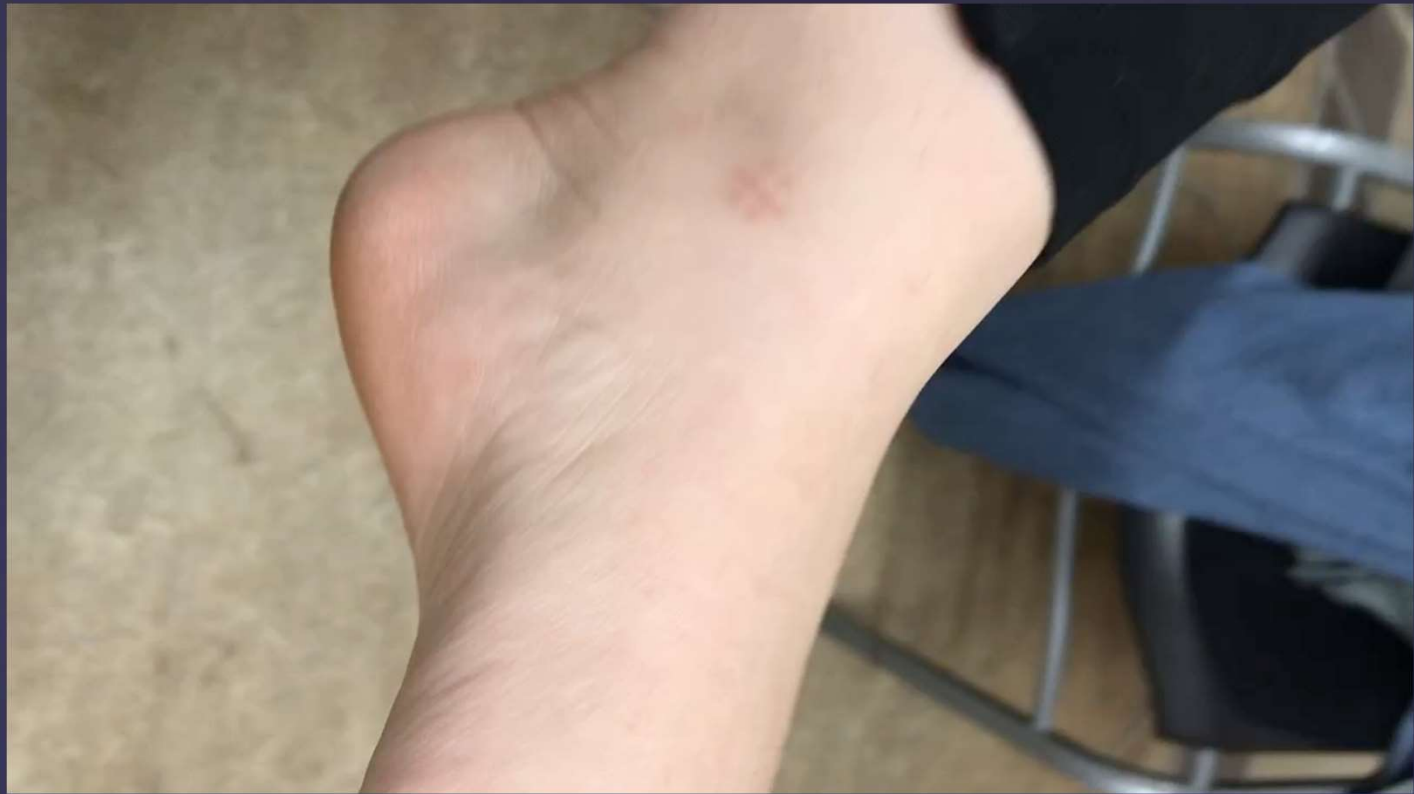{ Steven Shoemaker DPM FACFAS



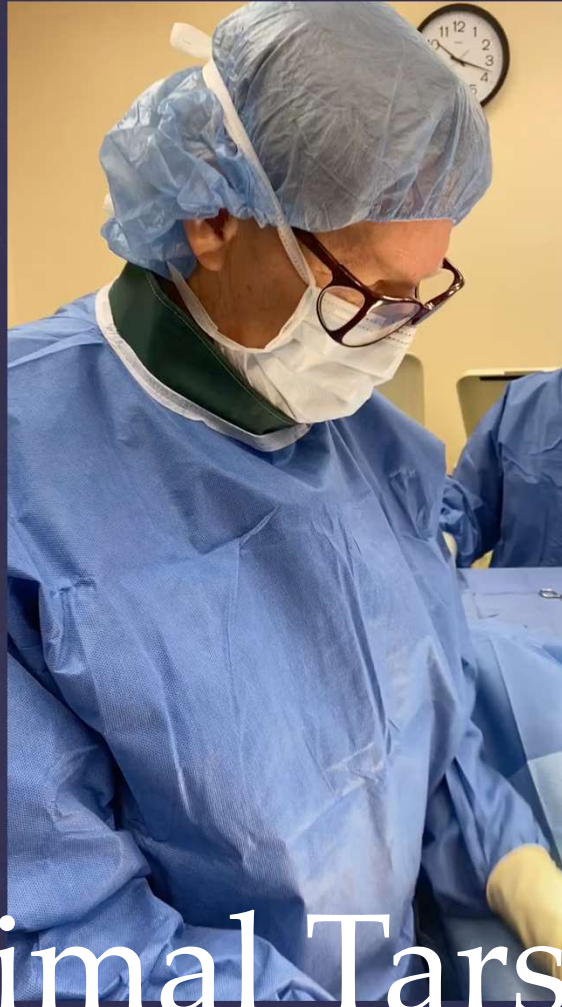Open approach what you need to see in your mind. And feel with your hands...video



Medial and lateral plantar
nn video



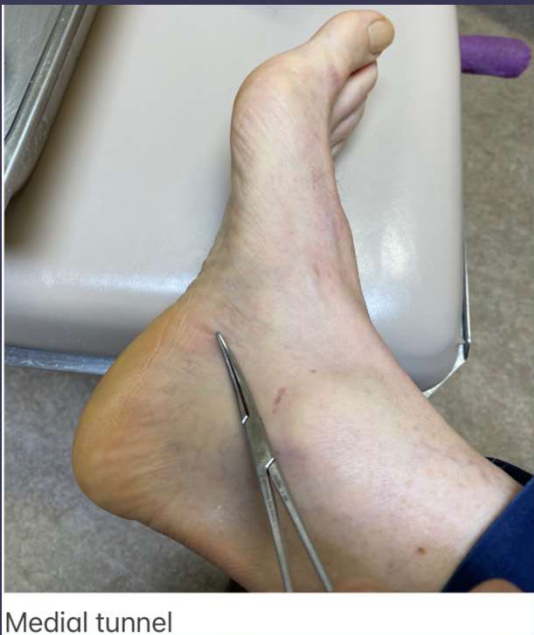Post op mis tarsal tunnel
release video



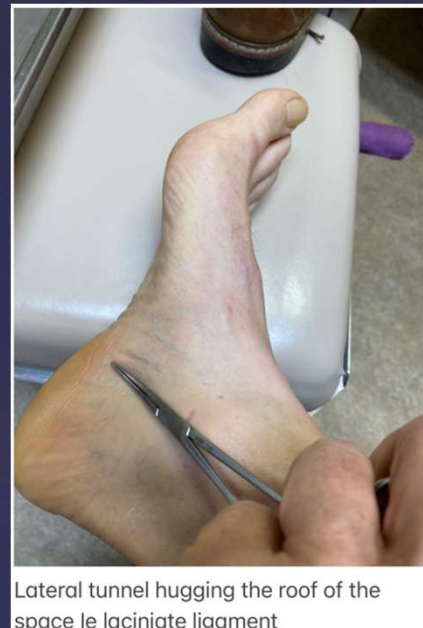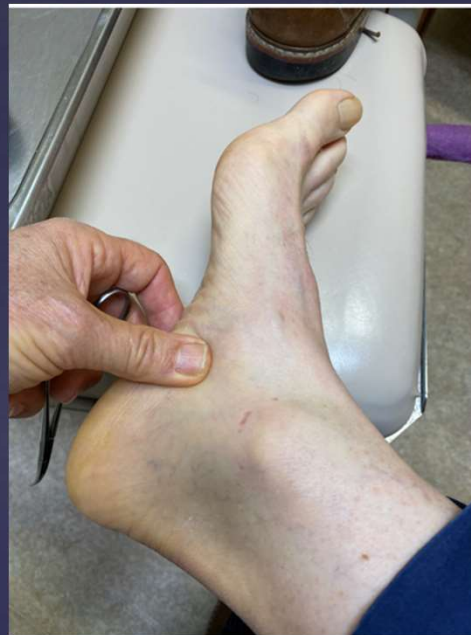MIS proximal Tarsal
tunnel release...one
surgeons experience

{ Porta pedis medial
plantar nn

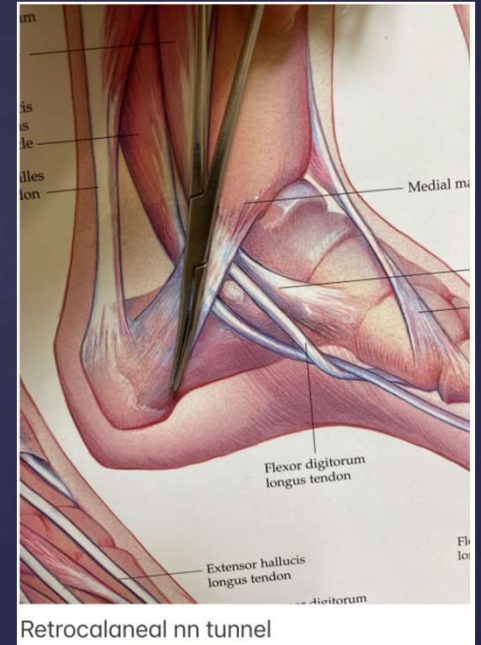
{ Lateral plantar nn



Medial tunnel

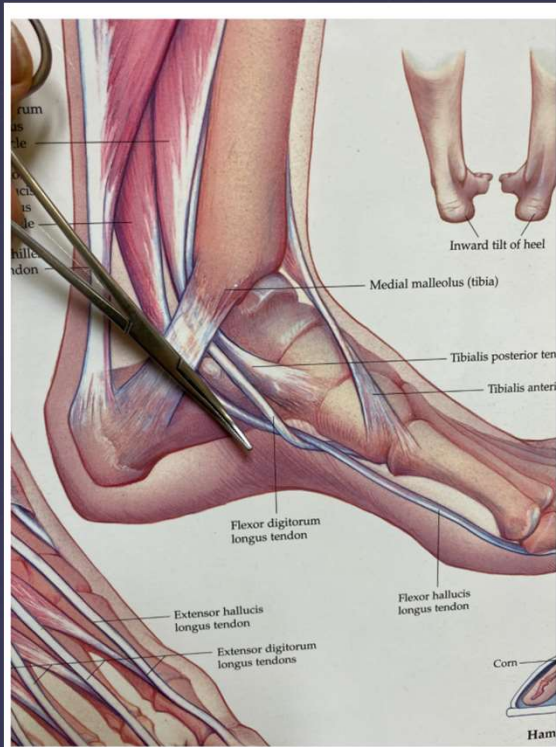


Lateral tunnel hugging the roof of the space between the ligaments

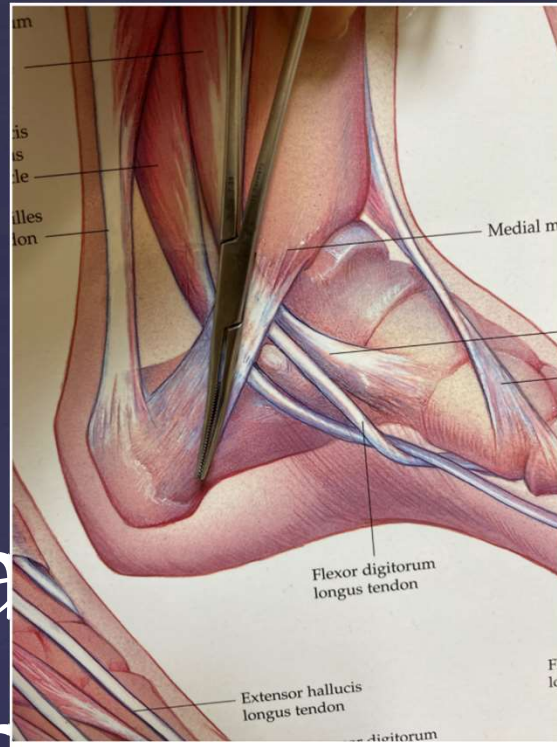


Retrocalcaneal nn tunnel

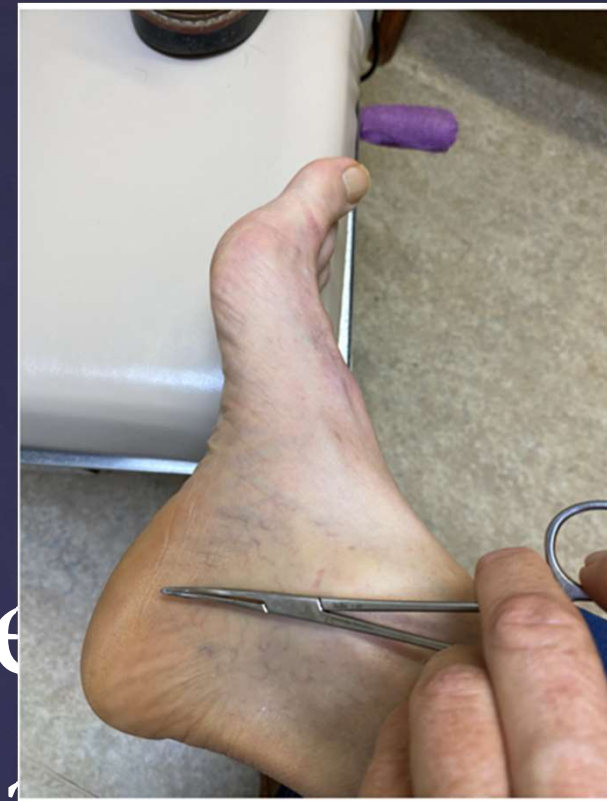Distal tunnel releases



Medial tunnel



Retrocalcaneal nn tunnel

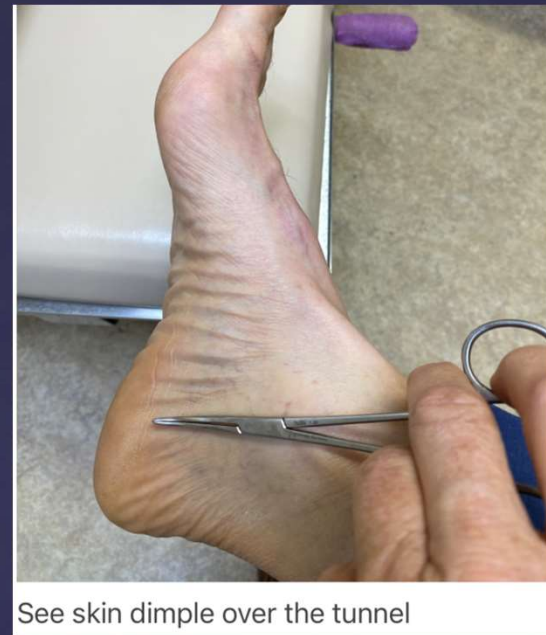
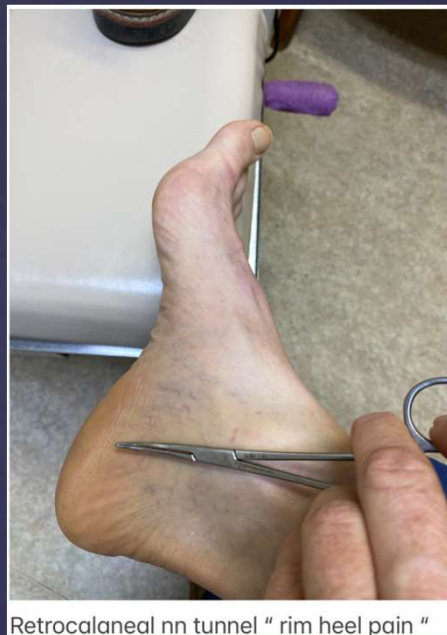

Retrocalcaneal nn tunnel " rim heel pain "

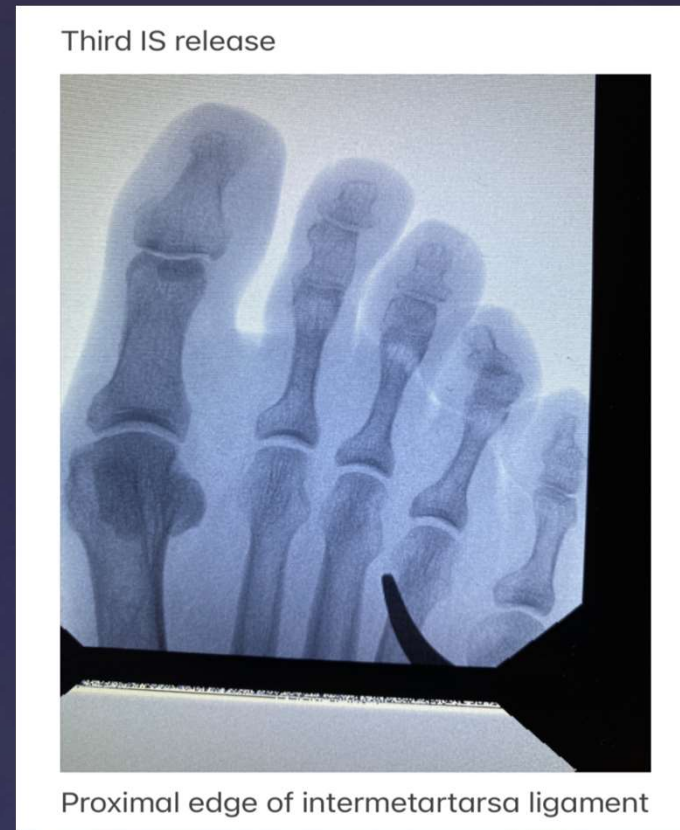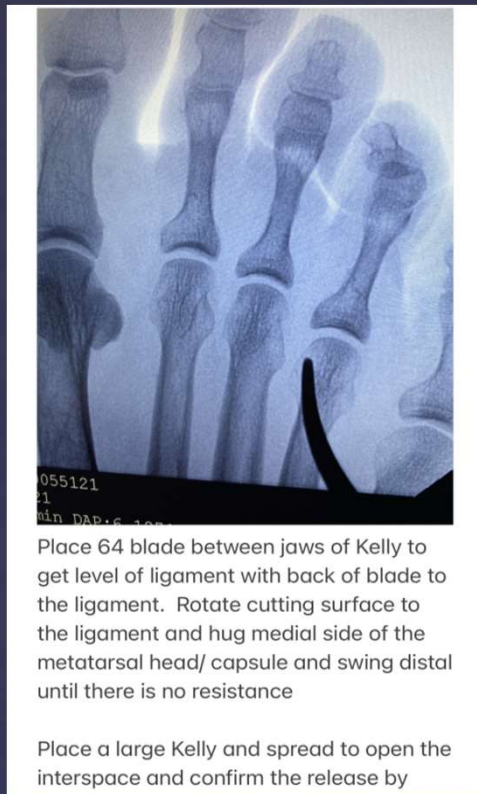them. Keep blunt tip against the Laciniated ligament and spread.

{ Recurrent calcaneal nn

{ Pucker sign: soft spot of tunnel



Rim heel pain, PF won't get better...think nerve or stress fracture.



- Intermetatarsal decompression: Spread with the hemostat at the heads to confirm on C-arm the expanding width of the intermetatarsal space. Consider metatarsal neck osteotomy to shorten and translate if needed.



Thank you: Keep it real